

Comparison of two methods of digital imaging technology for small diameter K-file length determination

Ehsani Maryam,⁽¹⁾ Abesi Farida,⁽²⁾ Akbarzade Farhad,⁽³⁾ Khafri Soraya⁽⁴⁾

Dental Materials Research Center, Assistant Professor, Department of Endodontics, Dental Faculty, Babol University of Medical Sciences, Babol, Iran⁽¹⁾

Dental Materials Research Center, Assistant Professor, Department of Oral & Maxillofacial Radiology, Dental Faculty, Babol University of Medical Sciences, Babol, Iran⁽²⁾

Dentist, Student Research Department, Dental Faculty, Babol University of Medical Sciences, Babol, Iran⁽³⁾

Assistant Professor of Social Medical and Health Department, Babol University of Medical Science, Babol, Iran⁽⁴⁾

Abstract

Objectives: Obtaining the proper working length in endodontic treatment is essential. The aim of this study was to compare the working length (WL) assessment of small diameter K-files using the two different digital imaging methods.

Methodology: The samples for this in-vitro experimental study consisted of 40 extracted single-rooted premolars. After access cavity preparation, the ISO files no. 6, 8, and 10 stainless steel K-files were inserted in the canals in the three different lengths to evaluate the results in a blinded manner:

1. At the level of apical foramen(actual)
2. 1 mm short of apical foramen
3. 2 mm short of apical foramen

A digital caliper was used to measure the length of the files which was considered as the Gold Standard. Five observers (two oral and maxillofacial radiologists and three endodontists) observed the digital radiographs which were obtained using PSP and CCD digital imaging sensors. The collected data were analyzed by SPSS 17 and Repeated Measures Paired T-test.

Results: In WL assessment of small diameter K-files, a significant statistical relationship was seen among the observers of two digital imaging techniques ($P<0.001$). However, no significant difference was observed between the two digital techniques in WL assessment of small diameter K-files ($P<0.05$).

Conclusion: PSP and CCD digital imaging techniques were similar in WL assessment of canals using no. 6, 8, and 10 K-files.

Keywords: K-file, Digital imaging, Working length.

Correspondence:

Abesi Farida

Dental Materials Research Center,
Assistant Professor,
Department of Oral & Maxillofacial Radiology,
Dental Faculty, Babol University of Medical Sciences
Babol, Iran

Tel: +981112291408-9

Cell phone: +989111150136

Fax: +981112291093

E-mail: f_abesi@yahoo.com

Introduction

One of the most important steps in a successful root canal therapy is the exact measurement of the working length of canal. An accurate assessment of WL is important for effective root canal debridement and obturation. WL is usually assessed using intra-oral radiograph imaging techniques which are the useful essential techniques in endodontics. Radiographs should demonstrate the exact position of the tip of the file in relation to the radiographic apex. ⁽¹⁾ Small diameter files like files ISO 6, 8 and 10 are usually used for WL determination in narrow and calcified and curved canals.

For WL determination, several studies have been done to compare digital and conventional systems and different digital systems. Most of these studies believed that there were no significant differences between these techniques in routine use like usual WL determination. ⁽²⁾ However; a little research has already been carried out about the accuracy of digital imaging systems in determining WL using the small diameter files. In two studies that have been conducted in 1998 and 2002, the conventional and digital radiography were similar to each other in diagnosing the small files close to the apex of the tooth. ^(3, 4) Nevertheless, Cederberg in 1998 found out that digital radiograph was better than conventional ones. ⁽⁵⁾ Friedlander LT et al. in 2002 compared the conventional and digital radiographies and concluded that when the file was inside the canal (at the level of apex or 2 mm short of it); the resolution of digital images was less than the conventional ones. ⁽¹⁾ But, Ravi et al. in 2012 compared conventional and direct digital radiography (DDR) in working length measurement of the root canal and assessed the significance of the different enhancement modes provided by the software to visualize the file length and showed that each of conventional radiography and DDR can be used for working length determination. The positive and colorize modes enhancement features of DDR greatly improve the visual perception, leading to more accurate measurements. ⁽⁶⁾

One study in 2010 compared CMOS (Complementary Metal-Oxide Semiconductor) and PSP (Photo Stimulable Phosphor Plate) digital imaging systems and has been shown that sensor type did not influence the outcome

of WL determination of small sizes when using high resolution imaging sensors. WL determination with ISO file 6 showed a significant difference compared to ISO 8 and 10 files but mostly for deviation < 1/5 millimeter. ⁽⁷⁾ And another study in 2011 compared Digora Optime®, CygnusRay MPS® and CDR Wireless® digital imaging systems and showed that the three digital radiographic imaging systems were accurate. The CDR Wireless system was significantly more precise in determining endodontic file lengths, and similarly to Digora Optime, was considered the least difficult to use when assessing endodontic file lengths. ⁽⁸⁾

Because a few study has been implemented on comparing PSP and CCD (Charge Coupled Device) digital imaging system in determining small diameter file, and given that the spatial resolution in Digora Optime and CCD: DiXi were 12-15 lp/mm (Line Pair/Millimeter) and 25lp/mm respectively, consequently the aim of this study was to assess the WL determination of small diameter K-files using two different methods of digital imaging CCD and PSP.

Methods and Materials

The sample for this in-vitro experimental study consisted of 40 extracted single-rooted premolars. After the extraction, the teeth were immediately stored in normal saline and 1% Thymol solution to prevent the bacterial growth. After being disinfected, access cavity was prepared for all the teeth using high speed turbine (NSK Inc. Japan) and diamond bur (Tizkavan co. Iran). The occlusal surface of the teeth was flattened with diamond bur to obtain a reference point.

The ISO files no. 6, 8, and 10 stainless steel K-files (MANI Inc, Japan). The files were inserted canals in three different situations in relation to the apex to evaluate the results in a blinded manner:

1. At the level of apical foramen (actual)
2. 1 mm short of apical foramen
3. 2 mm short of apical foramen

A digital caliper was used to measure the length of the files at the level of apical foramen. This length was considered as the gold standard. The radiographs were obtained using Minray (Kodak) intraoral radiographic device in a stable condition of 60 KVP and 8 MA in 0.2 seconds. The repeatable

radiographs were obtained with a film holder that specially designed for this purpose while the source-image-distance was 30 cm (SID=30 cm).

The teeth were radiographed using CCD sensor (DiXi3, Planmeca, Finland) with pixel size of 19 μm and resolution of 25 lp/mm and PSP (Optime, Soredex, Finland) with pixel size of 40 μm and resolution of 12 lp/mm according to the manufacturer's instructions. The conditions of the teeth and radiographic device were similar to previous method with the exception in reduction of exposure time to 0.1 second. The images of CCD sensor were directly observed on computer screen, but the images of PSP sensor were scanned and processed in Digora Pct (Soredex Finland), and were saved in computer. All the digital images were randomly coded.

Two oral and maxillofacial radiologists and three endodontists observed the digital radiographs simultaneously and an agreement was obtained. The measurement was done with a digital ruler and a single opinion was announced. The collected data were evaluated by SPSS 17 software and Repeated Measure Paired T-test.

Results

In WL assessment of small diameter K-files, statistical significant relationship was seen among the observers of two digital imaging techniques (Chart 1). Table1 shows descriptive statistic of two digital imaging techniques. In other words, regarding the length of file in the canal, no significant differences were observed between the two digital techniques of PSP and CCD in three file numbers of 6, 8, and 10 and real file length. The obtained results from the gold standard measurement were the same as the results of observers; therefore, the comparison and statistical analysis were not evaluated.

Table1. Descriptive statistic of two digital imaging methods in determining files number 6,8,10 in 1 mm and 2 mm short of apex

Method	Number	Mean \pm Std. Deviation
PSP6-1	40	18/59 \pm 2/092
CCD6-1	40	18/59 \pm 2/094
PSP8-1	40	18/59 \pm 2/096
CCD8-1	40	18/58 \pm 2/101
PSP10-1	40	18/58 \pm 2/106
CCD10-1	40	18/58 \pm 2/104
Actual	40	19/59\pm2/112
PSP6-2	40	17/59 \pm 2/111
CCD6-2	40	17/59 \pm 2/111
PSP8-2	40	17/59 \pm 2/111
CCD8-2	40	17/59 \pm 2/112
PSP10-2	40	17/59 \pm 2/105
CCD10-2	40	17/59 \pm 2/104

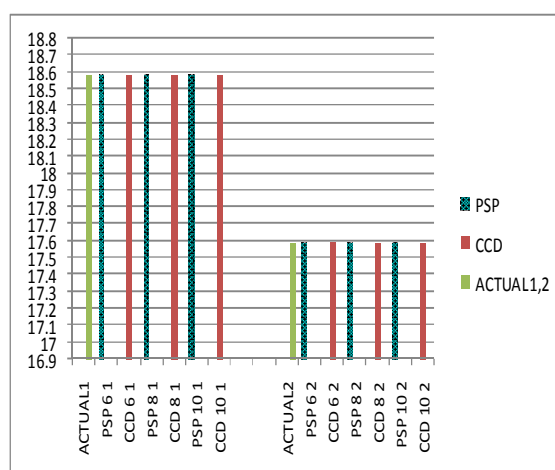


Chart 1. Comparison of the mean length with real length in 1 mm and 2 mm short of apex

Discussion

The precise measurement of WL, one of the most important steps of root canal therapy, could lead to successful endodontic treatment. Several studies have been carried out to compare digital imaging systems with conventional and other digital systems in determining WL.⁽³⁻¹²⁾ The results of this study showed that the assessment of WL using ISO file 6, 8, and 10 in PSP digital sensor was similar to CCD digital sensor. In other words, there was no significant difference in WL determination in root canal therapy procedure between the PSP and CCD techniques. Vandenberghe et al.⁽⁷⁾ compared the ability of two radiographic techniques (PSP and CMOS) in showing K-files no. 6, 8, and 10. The results showed that the observers mostly underestimated the lengths using PSP but overestimated them on CMOS. In addition, when using high resolution imaging sensors, the usage of different filters and diverse sensors did not show the significant differences in the measurement of small file sizes. In general, the standard errors of radiographic measurements with ISO file 6 were more than the standard errors of measurements with ISO 8 and 10 which could result from the small file sizes. Most of the deviations were less than 0.5 mm. But the interesting thing was that the electronic WL measurement showed a higher length than estimated on the radiographs. Therefore, they suggested that in WL determination with small file sizes, it was preferred to use the electronic WL measurement following radiography.

Athar et al.⁽¹¹⁾ compared three digital sensors (DenOptix; PSP, Gendex; CCD, and Schick;CDR/Wireless) in WL determination. Most of the errors were related to DenOptix whereas Gendex and Schick made fewer errors. In 2010, they compared the Gendex; CCD and DenOptix; PSP sensors for WL assessment in mandibular molars. The use of Gendex resulted in more reliable images than DenOptix.⁽¹²⁾

The purpose of the present study was to compare the reliability of high resolution PSP and CCD imaging systems for WL assessment of small endodontic files in root canal. Moreover, this in-vitro study could compare the ability of the mentioned devices in in-vitro condition and in reality. Therefore, we could possibly rely on the usage of the digital

imaging techniques in root canal therapy. In this study, because of being in-vitro, we could obtain actual length of the files and assess the real canal length and compare the lengths of the files in canals on the images.

In addition, to determine the lengths of the canals confidently, the occlusal surfaces of the teeth were flattened at the beginning. The determination of reference point in presence of cusps and occlusal pits of the teeth could increase the measurement errors. With occlusal surface flattening, we applied the rubber stops on the surfaces of the teeth properly and therefore, the measurements were repeatable.

In this study, two oral and maxillofacial radiologists and three endodontists observed the digital radiographs simultaneously. The reason was that the information might be different in the two fields. Then, the use of two types of expertise could be helpful in identifying images. In addition using multiple observers, would cause an error in the assessment of images was minimized. The measurement was done with a digital ruler and a single opinion was announced.

The observers were permitted to change the resolution of the images and announce the final decision. Therefore, the least measurement errors were made in the evaluation of each of the digital method. Consequently, we can conclude that PSP and CCD digital imaging techniques are similar in assessment of canals WL with the use of no. 6, 8, and 10 K-files.

Regarding the limited number of the studied teeth, to confirm the results of this study, further research should be conducted using digital radiographies.

Acknowledgment: The authors would like to thank Ziba Shirkhani for statistic analysis of this study and Dr. Evangeline Foronda for proofreading the manuscript.

References

1. Friedlander LT, Iove RM, Chandler NP. Comparison of phosphor-plate digital images with conventional radiographs for the perceived clarity of fine endodontic and periapical lesions. *Oral Surg Oral Med Oral Pathol Oral Radiol Endod.* 2002; 93:321-7.
2. White SC, Pharoah MJ. Oral radiology: principles and interpretation. In: John B,

- Ludlow and André Mol. *Digital imaging*. 6th ed. Mosby Elsevier, St. Louis 2009; 78-99.
3. Fuge KN, Stuck AM, Love RM. A comparison of digitally scanned radiographs with conventional film for the detection of small endodontic instruments. *Int Endod J* 1998; 31:123-6.
 4. Menten A, Gencoglu N. Canal length evaluation of curved canals by direct digital or conventional radiography. *Oral Surg Oral Med Oral Pathol Oral Radiol Endod*. 2002; 93:88-91.
 5. Cederberg RA, Tidwell E, Frederiksen NL, Benson BW. Endodontic working length assessment. Comparison of storage phosphor digital imaging and radiographic film. *Oral Surg Oral Med Oral Pathol Oral Radiol Endod*. 1998; 85:325-8.
 6. Ravi V, Lipee P, Rao CV, Lakshmikanthan L. Direct digital radiography versus conventional radiography - assessment of visibility of file length placed in the root canal: An in vitro study. *J Pharm Bioallied Sci*. 2012; 4:285-9.
 7. Vandenberghe B, Bud M, Sutanto A, Jacobs R. The use of high-resolution digital imaging technology for small diameter K-file length determination in endodontics. *Clin Oral Investig*. 2010; 14:223-31.
 8. Oliveira ML, Ambrosano GM, Almeida SM, Haiter-Neto F, Tosoni GM. Efficacy of several digital radiographic imaging systems for laboratory determination of endodontic file length. *Int Endod J*. 2011; 44, 469-73.
 9. Ezoddini Ardakani F, Goodarzi Pour D, Soltani Mohammadabady M. Comparison of the accuracy of digital and conventional radiography in evaluation of curved canals lengths. [Article in Persian]. *Journal of Dental Medicine*. 2005; 18(3): 67-74.
 10. Goga R, Chandler NP, Love RM. Clarity and diagnostic quality of digitized conventional intraoral radiographs. *Dentomaxillofac Radiol*. 2004; 33:103-7.
 11. Athar A, Angelopoulos C, Katz JO, Williams KB, Spencer P. Radiographic endodontic working length estimation: comparison of three digital image receptors. *Oral Surg Oral Med Oral Pathol Oral Radiol Endod*. 2008; 106:604-8.
 12. Anas A, Asaad J, Tarboush K. A Comparison of intra-oral digital imaging modalities: Charged Couple Device versus Storage Phosphor Plate. *Int J Health Sci (Qassim)*. 2010; 4:156-67.